

Comparison between Vertical Scar and Wise Pattern Methods of Superior Pedicle Reduction Mammoplasty; Surgical Modifications

AHMED M. KENAWY, M.D.; SHEHAB S.H. SOLIMAN, M.D.; MOHAMED A.E. EL-MAHROUKY, M.D. and FATHY R.F. KHODAIR, M.D.

The Department of Plastic & Reconstructive Surgery, Faculty of Medicine, Cairo University,.

ABSTRACT

Supporters of the vertical mammoplasty state that the resultant breast shape and scar are superior to the wise pattern superior pedicle breast reduction. This study contains a comparison of the vertical scar reduction with the wise pattern superior pedicle reduction by analysis of pre- and postoperative photographs with our personal modifications to the superior pedicle technique. All the patients (moderate and large reductions) had adequate standard pre- and postoperative photographs between 2008 and 2010. Esthetic appearance, symmetry, areola-nipple complex quality, and scarring were assessed. We have added some modifications to the superior pedicle reduction concerning the lateral dog-ear at the end of the wound, the rotation of the flap, the intra-operative measurements and the amount of glandular tissue resected.

INTRODUCTION

Breast reduction is supposed to resolve the functional and aesthetic problems for females with macromastia. This operation has been highly accepted by women all over the world as it increases the satisfaction and decreases the functional problems of large breasts [1]. Breast reduction has evolved a debate between plastic surgeons, as evidenced by the different modalities of the surgical techniques available. Previously, the surgeon and the patient had to choose either a beautiful shape and long scars or short scars with a less beautiful shape [2].

The inverted-T-scar breast reduction, still the most used technique, is a prime example of a technique that gives a very good shape but leaves long scars. On the contrary, the vertical technique leaves short scars but is assumed to create less beautifully shaped breasts [2,3].

The ideal reduction mammoplasty should produce a perfect breast size, shape, projection, symmetry, with minimal scarring and normal nipple sensation. Also the technique should be easy, expeditious, reproducible, with lower morbidity rates

and easy to learn by most plastic surgeons [4]. In determining the technique to be used in breast reduction, the technique must be thought of as having two separate and independent components:

- 1- Re-positioning the nipple-areola complex (NAC).
- 2- Adjustment and re-draping of the skin [5].

The superior pedicle vertical reduction mammoplasty technique initially described by Lassus [6] and refined by Lejour [7] has been slowly gaining acceptance. The technique was designed to avoid late loss of projection while allowing easy transposition of the nipple-areola complex [8].

“Scar Wars” was an excellent expression mentioned in the national and international meetings among the leading surgeons whether the vertical or the T-shaped superior pedicle reduction mammoplasty is superior. The vertical reduction supporters assume that the smaller scar is better and resultant breast shape and projection is superior due to suturing the lateral and medial pillars together [8], and also says that the technique has a similar rate of early complications (i.e. hematoma, seroma, wound dehiscence, infection and necrosis) and late complications (i.e. problems of volume, shape, symmetry, areola and scars) as that of the inverted T-scar technique [9,10].

However, there are only a few scientific studies that compare the 2 techniques. Significant findings comparing a group of females with moderate and large reductions (average reduction 500g to 1000g) have shown that the vertical reduction patients are more satisfied with their scars but have a higher rate of revision [8,11].

In choosing the management of the skin and the parenchyma we believe that there is a limit to

the amount of resection in both elements that can be produced with the vertical reduction. Also the previous authors believe that there are increased late complication rates [5]. We describe here our method in superior pedicle breast reduction with our modifications in the vertical and wise pattern inverted T-scar especially with the design, decision making, modes of resection and suturing vectors and we evaluate the morbidity rate, patient satisfaction and re-operation rate.

PATIENTS AND METHODS

A prospective series of 92 patients aged between 20 and 53 years (mean: 41 years) were operated on between January 2008 and December 2009 and their postoperative follow-up continued till July 2010 at Kasr El-Aini Hospital at Cairo University. All of them had a bilateral superior pedicle breast reduction procedure, with a minimum average of at least 300g per breast removed and a maximum 35cm from midclavicular point to nipple position. Out of these, 30 patients had a vertical scar breast reduction (VSBR), where 24 patients had a primary reduction and 6 patients had a secondary (redo) reduction. The other 62 patients had a wise pattern breast reduction (WPBR), where 40 patients had a primary reduction and 22 patients had a secondary reduction (Table 1).

All the operations were performed by the same team of plastic surgeons and assistants. All patients, irrespective of their age, were offered a preoperative clinical examination, detailed measurements, digital photographic documentation and base-line mammography. Also, we discussed with all of them the plan of reduction (preoperative markings), the choice of their reduction whether vertical or wise pattern superior pedicle procedure and the expected postoperative steps and an Informed consent were taken. The 28 patients, who presented to us with previously bilateral reductions, were questioned for:

- When was the primary reduction done?
- Why were the patients not satisfied?
- Which pedicle was used? (if they know or remember).
- Was there any morbidity postoperative?

We recorded our modifications in both vertical and wise pattern superior pedicle breast reduction. The postoperative follow-up included clinical examination and measurements (i.e. midclavicular to nipple, length of vertical scar, projection, areola width and shape, etc.) and digital photographic documentation of the patients after 1, 3 and 6

months and their postoperative follow-up ranged from 6 to 13 months. We recorded the postoperative early complications (i.e. hematoma, seroma, delayed healing, nipple necrosis, infection, etc.) and late complications (i.e. asymmetry, scarring, unsatisfaction, etc.). Additionally, our visual impression was recorded since "perfect numbers" in measurements don't necessarily correspond to "beautiful breasts".

Technique modifications:

All patients were measured and marked sitting or standing preoperatively by the senior author. The new nipple position was marked on the midline of the breast, on or 1cm above the submammary fold according to the bimanual test and mid arm position. The modifications in the intraoperative technique included the following steps:

- 1- Nipple-areola complex (NAC) transposition.
- 2- Vertical incision.
- 3- Projection of the breast.
- 4- Lateral contouring of the breast.

NAC transposition:

The method of NAC transposition, whether in the VSBR or WPBR, was determined by the distance required to move to the new position. If this was less than 5cm a superior pedicle glandular-based transposition was performed. From 5cm to 12cm an elevated superior dermo-glandular pedicle was used as in Fig. (1A).

Vertical incision:

After NAC transposition, three stay sutures were needed (especially in VSBR); the first suture was taken from the superior pole of the areola to its new position, the second suture was taken from the ends of the new areola edges to each other with a stay suture also from medial to lateral pillars and the third one was taken at the inferior end of the vertical incision after its measurement intraoperative with average 6 to 7cm as in Fig. (1B).

A bulge inferior to the third suture might appear, if this bulge was less than 2cm in length, removal of its fat and tucking it in the vertical suture line were done, if this bulge was more than 2cm in length, certain steps were done to remove it and insert the vertical incision in the inframammary fold incision; we held and stretched both medial and lateral ends of the bulge till two medial and lateral triangles appeared (Fig. 1C), then an incision was done from the point of the third suture to the inframammary fold drawn preoperative (Fig. 1D), the two triangles were dissected till the pectoral fascia on the inframammary fold (Fig. 1E), the

two triangles were held up and resected through the inframammary fold from the medial to lateral points.

Projection of the breast:

After the previous modifications in VSBR and WPBR, a fourth suture was taken from the point of the third suture to the point of the meridian of the breast, if more projection or superomedial bulge were needed, this fourth suture was moved 1 to 2cm medially and done bilaterally to gain symmetry (Fig. 1F).

Lateral contour of the breast:

There were two modifications to get a smooth lateral contour; the first one was holding the superior wound of the lateral incision of the inframammary incision, approximating it medially till it showed the whole lateral round fullness of the breast and suturing the fascia in this point above and below to each other (Fig. 1G). The second one was removal of fat from the end of the lateral incision till we got a smooth curve with the lateral thoracic wall (Fig. 1H).

RESULTS

From the 92 patients came requesting reduction mammoplasty, 28 patients came requesting redo reduction mammoplasty and all of them did vertical scar reduction mammoplasty several years ago (Lejour's technique). These patients were questioned for the reasons for re-reduction of their breasts and the questionnaire revealed that they complained of some unsatisfied results such as highly positioned nipple areola complex (NAC) (Fig. 2A), hypertrophic scarring (Fig. 2B), widening (Fig. 2C) or resistant ulcer due to scar tension (Fig. 2D), inferior dog-ear in the vertical scar (Fig. 2E), extension of the scar below the inframammary fold (Fig. 2F), very long vertical scar (more than 8cm), inferior breast bulge (Fig. 2G), lateral breast fullness (Fig. 2H), asymmetrical breasts and/or NAC position (Fig. 2I) or still larger in size than they expected from the previous reduction (Table 2).

After accurate assessment 6 patients were scheduled for redo VSBR technique and 22 patients for WPBR technique.

Results showed no statistically significant difference between the 2 groups regarding age, operative time and body mass index (BMI). Although the operative time was shorter in the vertical-reduction patients than the wise-pattern patients, there was no statistical difference.

Average amount of breast excised was weighed. The midclavicular point to the nipple (MC-N) distance was measured pre- and post-operatively and also the vertical scar length postoperatively after 6 months. These numbers showed no significance except for the vertical scar length and the weight of the amount excised from each breast (Table 3).

Rates of complications (early and late) were higher in the wise-pattern breast reduction but did not reach statistical significance except for later revision of the scars, breast shape and asymmetry where vertical-reduction patients were higher than the wise-pattern patients (Table 4).

Table (1): Vertical vs. Wise patients based on their number.

Operation	Total no.	1ry	2ry
VSBR	30	24	6
WPBR	62	40	22

Table (2): Number of patients with previously unsatisfied results.

Previously unsatisfied result	No. of patients
Highly positioned NAC	6
Asymmetry	3
Hypertrophic scarring	2
Widening of the scar	5
Scar tension	1
Dog-ear	14
Long scar (>8cm) or extension	7
Inferior breast bulge	8
Lateral breast fullness	5
Unsatisfactory previous reduction	22

Table (3): Demographic data of the measurements.

	VSBR	WPBR
MC-N (preoperative)	27 (± 3 cm)	31 (± 4 cm)
MC-N (postoperative)	20 (± 1 cm)	22 (± 1 cm)
Vertical scar length (6m)	9 (± 2 cm)	8 (± 1 cm)
Excision per side (average)	650 (± 350 g)	950 (± 400 g)

Table (4): Early and late complications in vertical scar and wise pattern breast reduction patients.

	VSBR	WPBR
Infection	1	1
Minor dehiscence	2	5
Hematoma	1	1
Fat necrosis	1	2
Hypertrophic scar	2	1
Partial nipple loss	0	1
Total nipple loss	0	1
Revision of scars	2	4
Inferior and lateral bulge	1	2
Dog-ear	3	3
Asymmetry	1	1

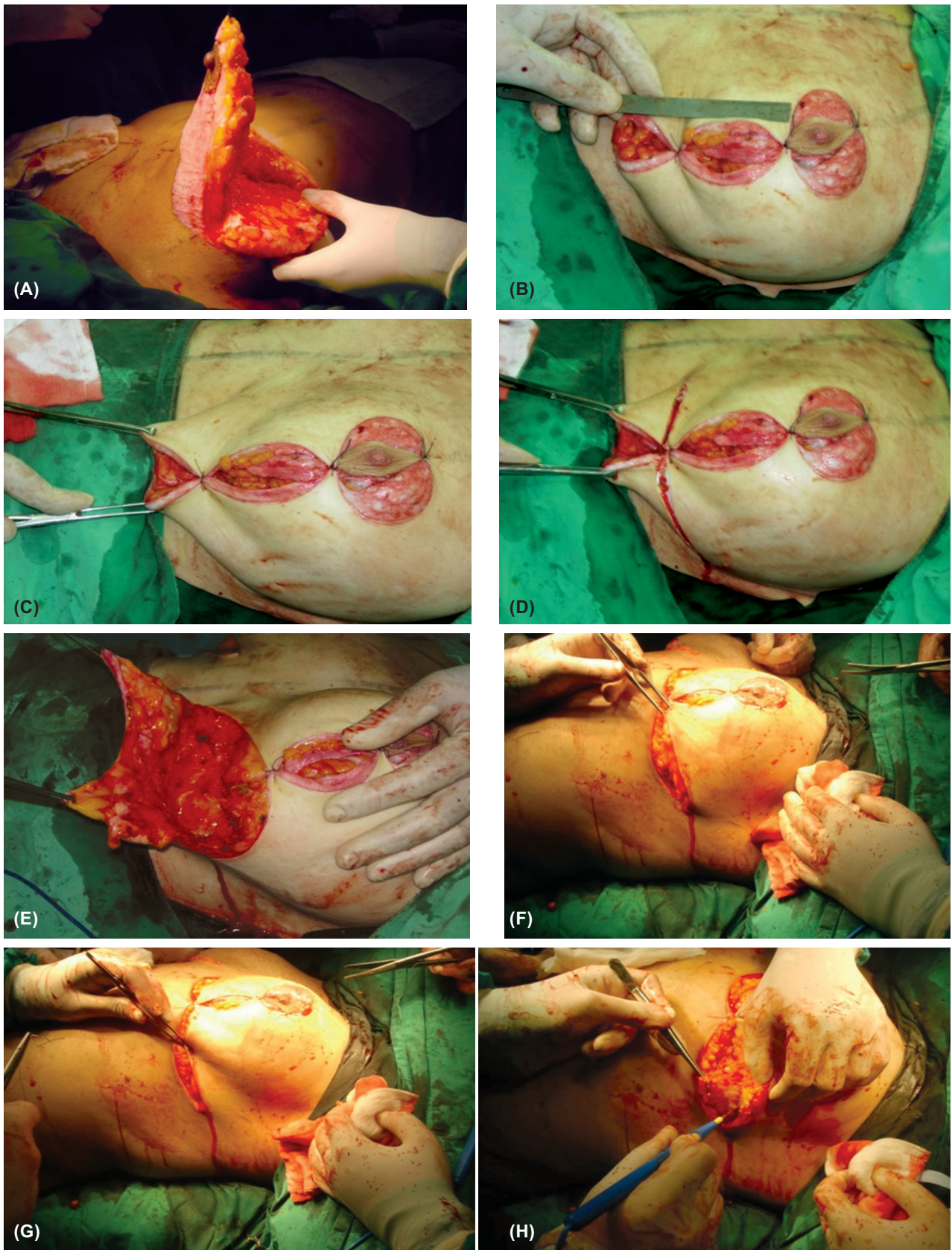


Fig. (1): Modifications in the technique (a) NAC transposition in superior dermo-glandular pedicle, (b) Measurement of the vertical incision and taking the three sutures, (c) Identification of the medial and lateral triangles in the inferior bulge, (d) The incision from the third suture to the inframammary fold, (e) Dissection of the two triangles to the pectoral fascia, (f) Transposition of the T-suture 1-2cm medially to gain more projection bilaterally, (g) Medial approximation of the lateral portion of the inframammary incision superiorly, and (h) Removal of fat from the lateral end to have a smooth curve.

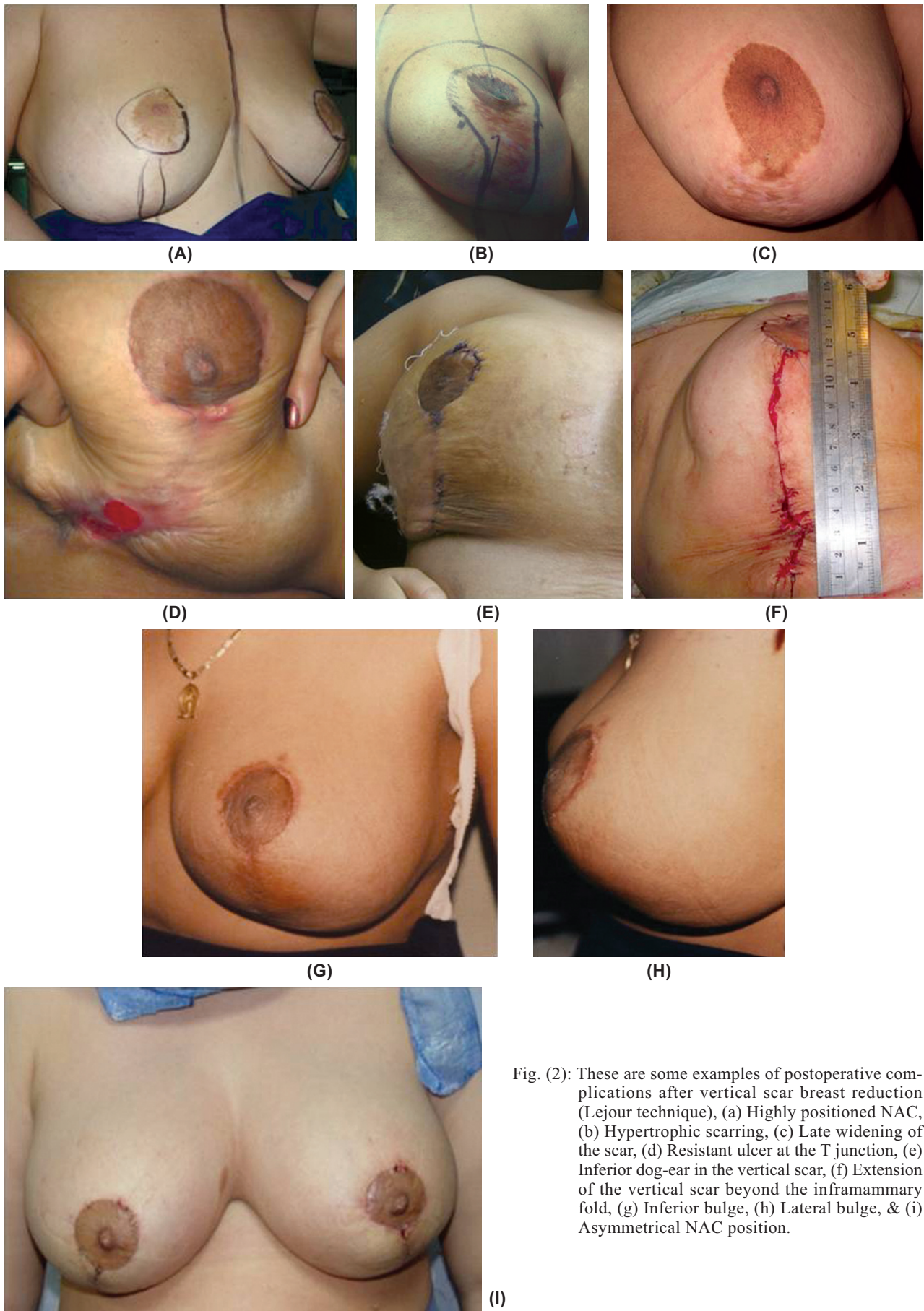

Fig. (2): These are some examples of postoperative complications after vertical scar breast reduction (Lejour technique), (a) Highly positioned NAC, (b) Hypertrophic scarring, (c) Late widening of the scar, (d) Resistant ulcer at the T junction, (e) Inferior dog-ear in the vertical scar, (f) Extension of the vertical scar beyond the inframammary fold, (g) Inferior bulge, (h) Lateral bulge, & (i) Asymmetrical NAC position.

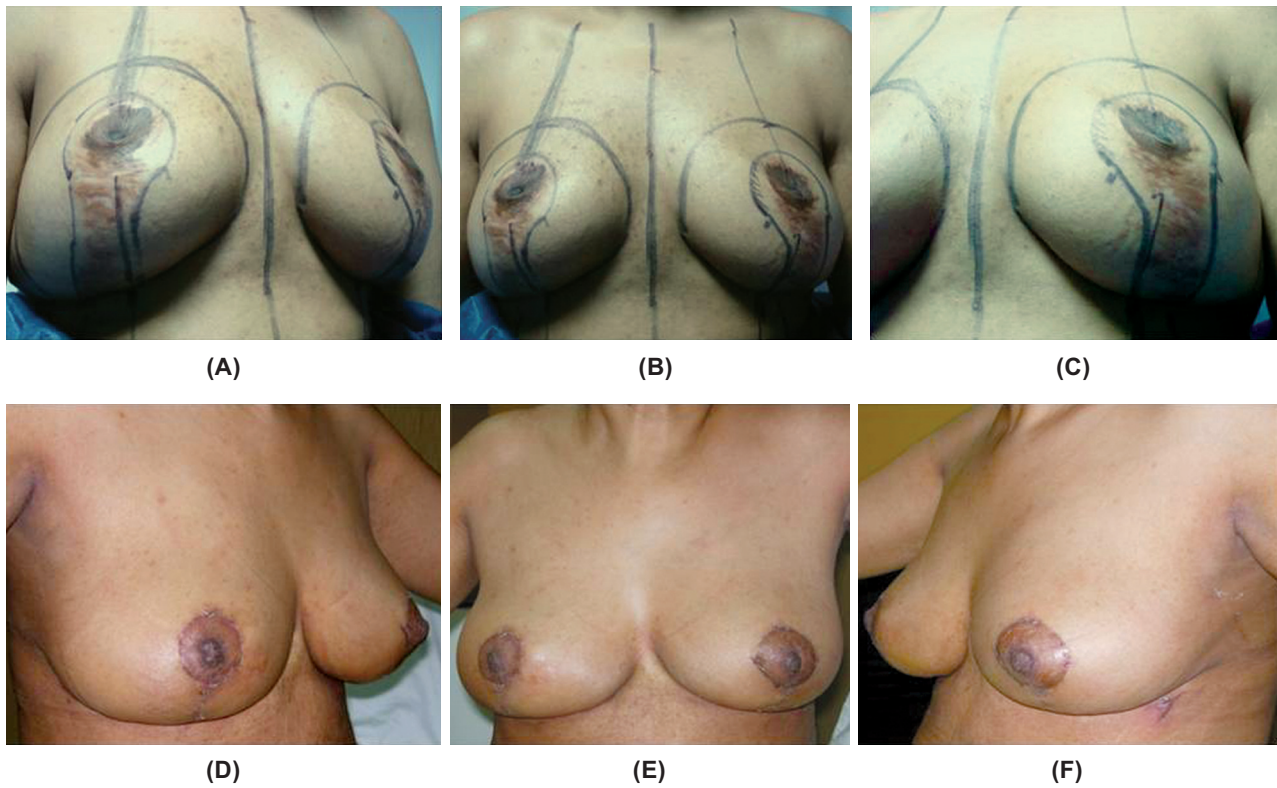


Fig. (3): A 37 years old lady had done (a), (b), (c) Lejour reduction mammoplasty with postoperative widened vertical scar & highly positioned NAC, (d), (e), (f) Revision by modified wise pattern breast reduction was done.

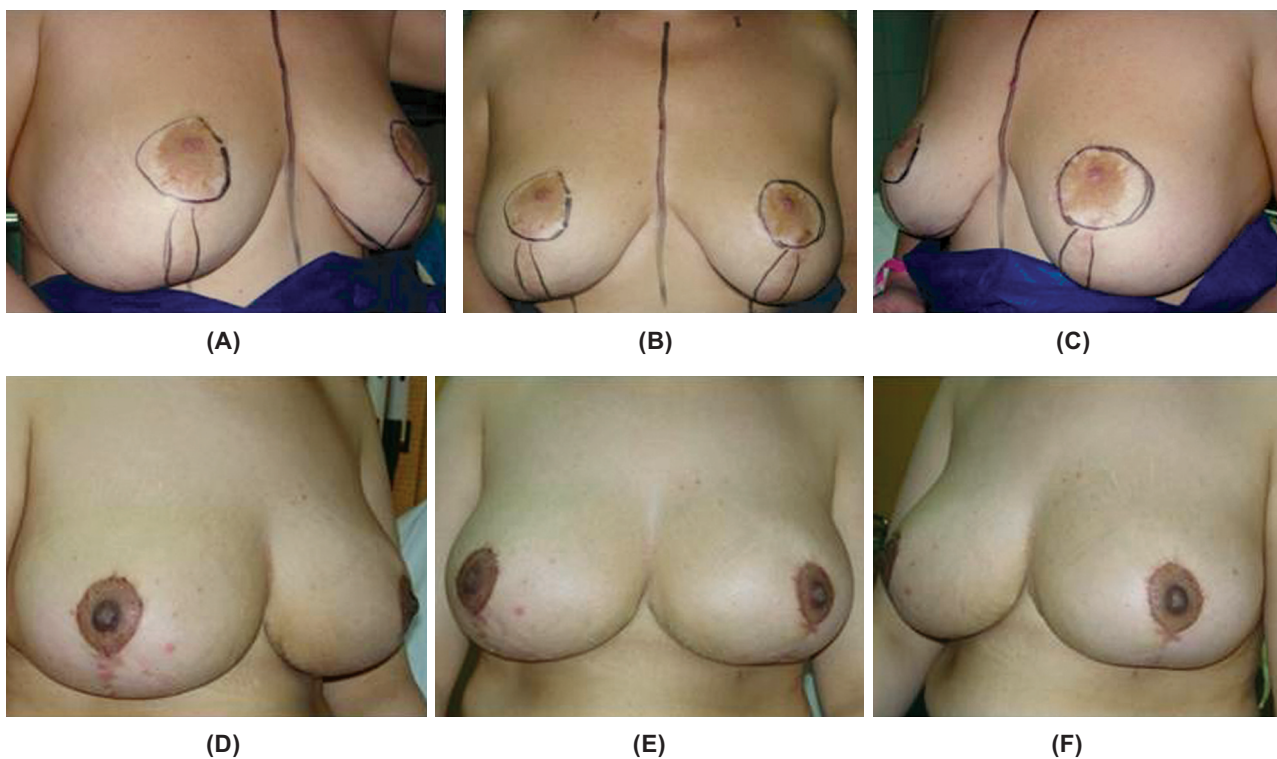


Fig. (4): A 42 years old lady had done (a), (b), (c) vertical scar breast reduction (Lejour technique) with postoperative inferior bulge, lateral fullness & mal-positioned NAC, (d), (e), (f) redo by modified wise pattern breast reduction was done.

Early complications were 23.3% in VSBR and 19.4% in WPBR patients which showed no statistical significance. The minor dehiscence in WPBR mostly was at the T junction between the inframammary and the vertical incision but all of the patients subsequently healed with conservative treatment only and no late complications. 6.7% of VSBR and 4.8% of WPBR patients complained that their breasts were larger in volume (esp. inferior bulge and lateral fullness) and asymmetrical in shape than what they expected which showed a great statistical significance in patient satisfaction. 6.7% of VSBR and 6.5% of WPBR patients needed later revision of scars (esp. the vertical scar in both groups). 10% of VSBR patients required excision of a dog-ear from the inferior aspect of the vertical scar in both breasts while only 4.8% of WPBR patients needed excision of a dog-ear from the lateral end of the inframammary scar in unilateral breast in 2 patients and in bilateral breasts in one patient.

DISCUSSION

With any operation, the surgeon's results improve with experience. The usage of superior pedicle in reduction mammoplasty had proven to be a very reliable flap for huge breasts (with maximum 35cm in length from midclavicular point to the nipple). We had only 2 partial necrosis of the areola in our patients, probably due to subareolar hematoma, and 1 complete necrosis of the areola, probably due to compression of the breast parenchyma from below on the pedicle and the patient was smoker, but in the rest of the patients (89 patients), nipple-areola complex showed no complication. As for the aesthetic appearance and patient satisfaction, they showed a marked improvement especially after the modifications that we applied for both procedures which had enhanced the nipple-areola complex, the vertical scar, the symmetry of both breasts, the projection, the ablation of the dog-ears and the lateral contouring as mentioned before.

The vertical reduction mammoplasty learning process is challenging to teach. Many surgeons are apprehensive to undergo the learning curve for this procedure for a variety of reasons so we summarized the benefits and the pitfalls of each procedure in many aesthetic points such as the scar quality, the volume, the symmetry, the lateral and medial transverse axis, the supra-areolar area, the infra-areolar area and the nipple-areola complex.

Scar quality:

In the VSBR technique, there is more tension in the scar which sometimes leads to wound dehiscence (6.7%), the scar frequently shows inferior dog-ear (10%), late widening and extension below the inframammary fold. In the WPBR technique, there is less tension in the scar, no dog-ear inferiorly but sometimes laterally due to axillary and lateral chest wall fullness, no extension of the scar below the inframammary fold and usually the transverse scar is hidden and cannot be assessed on standard postoperative photographs but there are some pitfalls in the scar of this technique, the scar sometimes shows minor dehiscence especially at the inferior T junction (8.1%) and rarely extensive hypertrophic scarring especially in the transverse scar at the medial end (1.6%).

Volume, projection and symmetry:

The volume is easily adjusted in both techniques according to the patient wish and personal demand. In the VSBR technique there is always larger final volume because the more breast parenchyma is resected, the greater the risk of producing tube-shaped breasts, it is more difficult to acquire equality and symmetry (3.3%) in both breasts and the revision of those previous morbidities is difficult but there is always more enhancement in the projection and also long lasting. In the WPBR technique, there is more control of the parenchyma resection and both breasts symmetry (only 1.6% of the patients showed asymmetry) and revision, if needed, is easier but the projection is lesser.

Breast contour:

The observation of the four aesthetic areas postoperative that determine the breast contour, including the superomedial area, the lateral contour, the supra-areolar area and the infra-areolar area, is very crucial. In the VSBR, there is always more lateral and axillary fullness (3.3%), persistent cranial convexity and sometimes inferior bulge but the superomedial area fullness is always perfect. In the WPBR, it is always easy to control the lateral contour and the superomedial bulge especially after its modification that was mentioned before, also it is simpler to get a more ideal smooth straight line in the supra-areolar area and to avoid the inferior bulge and the later breast bottoming.

Nipple-areola complex:

In the VSBR, there is frequently highly positioned NAC and always facing upwards due to the later inferior bottoming or conical in shape due to excessive tightening of the medial and lateral

parenchymal pillars, but in the WPBR, it is easier to adjust the position, shape and bulge of the NAC.

Conclusion:

The majority of reduction mammoplasty operations result in improvement in patient satisfaction and aesthetic results. The patient's expectations are highly influenced by the preoperative detailed consultation, markings and aesthetic expectations. Most patients must be told about the high probability of at least a minor wound complication.

Although in our practice superior pedicle reduction mammoplasty is reserved for medium and slightly large breasts, with the modifications mentioned for this technique, it can be used for a variety of breast sizes and shapes. It is easy to learn and teach, quick to perform, safe in redo reductions, and can provide lasting cosmetic results especially for long-term maintenance of the areola and upper pole projection. The occurrence of morbidities was not significant. Additional interventions were rarely needed and only for patients who desired further decrease in their breast sizes.

We believe there is a limit to the amount of skin shrinkage that can be reached with the vertical scar breast reduction technique and that beyond this limit, there is an increased complication and revision rate. With the exact selection of patients by preoperative measurements and consultation, the incidence of complications can be minimized. We have modified a straightforward marking system to select a technique, with a simple horizontal resection, minimizing complications and revision operations.

REFERENCES

- 1- Malata ChM. and Bostwick J.: Breast reduction with the superior parenchymal pedicle: T-scar approach. *Operative techniques in Plastic and Reconstructive Surgery*, 6: 126-135, 1999.
- 2- Beer G.M., Morgenthaler W., Spicher I. and Meyer V.E.: Modifications in vertical scar breast reduction. *Br. J. Plast. Surg.*, 54: 341-347, 2001.
- 3- Pitanguy I.: Surgical treatment of breast hypertrophy. *Br. J. Plast. Surg.*, 20: 78-85, 1967.
- 4- Malata C.M., Hodgson E.L., Chikwe J., Canal A.C. and Purushotham A.D.: An application of the LeJour vertical mammoplasty pattern for skin-sparing mastectomy: A preliminary report. *Ann. Plast. Surg. Oct.*, 51 (4): 345-50, 2003; discussion 351-2.
- 5- Dex E.A., Asplund O., Ardehali B. and Eccles S.J.: A method to select patients for vertical scar or inverted-T pattern breast reduction. *J. Plast. Reconstr. Aesthet. Surg.*, 2007; in press. doi: 10.1016/j.bjps.2007.09.013.
- 6- Lassus C.: Evolution of a technique: A single vertical scar. *Aesthetic. Plast. Surg.*, 11: 107-112, 1987.
- 7- Lejour M.: Vertical mammoplasty and liposuction of the breast. *Plast. Reconstr. Surg.*, 94: 100-114, 1994.
- 8- Kreithen J., Caffee H., Rosenberg J., Chin G., Clayman M., Lawson M. and Seagle M.B.: A comparison of the Lejour and wise pattern methods of breast reduction. *Ann. Plast. Surg.*, 54: 236-242, 2005.
- 9- Ferreira M.C.: Evaluation of results in aesthetic plastic surgery: Preliminary observations on mammoplasty. *Plast. Reconstr. Surg.*, 106: 1630-1638, 2000.
- 10- Beer G.M., Spicher I., Cierpka K.A. and Meyer V.E.: Benefits and pitfalls of vertical scar breast reduction. *Br. J. Plast. Surg.*, 57: 12-19, 2004.
- 11- Cruz-Korchin N. and Korchin L.: Vertical versus wise pattern breast reduction: Patient satisfaction, revision rates, and complications. *Plast. Reconstr. Surg.*, 112: 1573-1579, 2003.